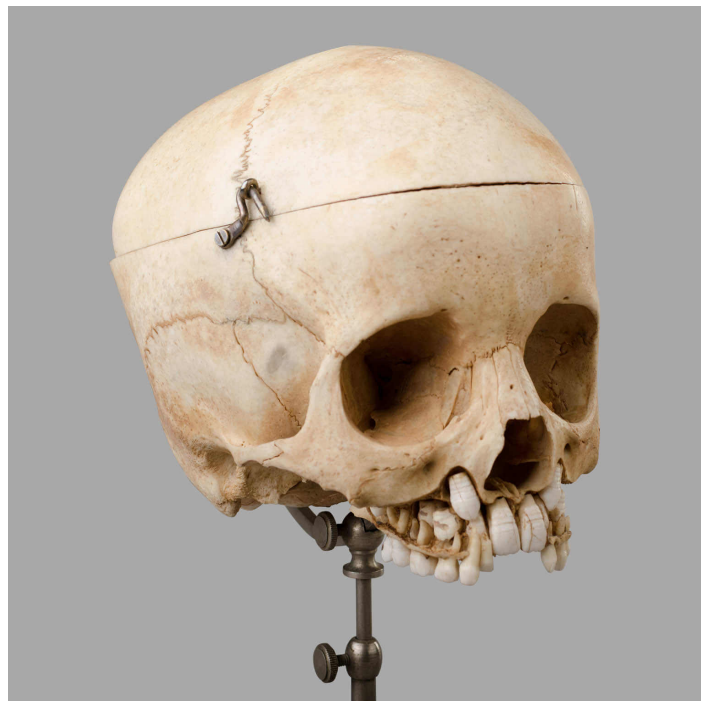

PRÉPARATION DENTAIRE, FIN XIXEME

UGS : 1565



PRODUCT DESCRIPTION

Crâne d'enfant avec dents de lait et dents definitives.

Dimensions : H. 29 cm x l. 14 cm x Prof. 18 cm

GALLERY IMAGES

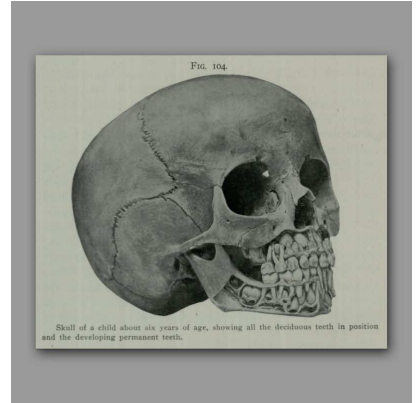
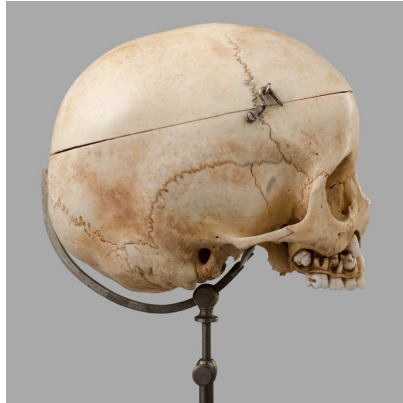
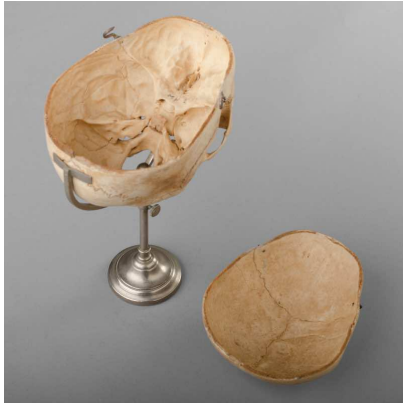
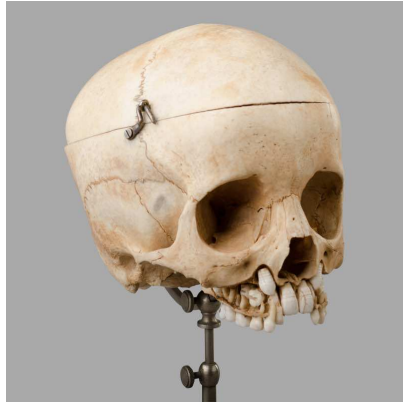FIG. 104
Skull of a child about six years of age, showing all the deciduous teeth in position and the developing permanent teeth.